

G. Negri  
S. Grassi  
M. Zappia  
S. Cappabianca  
P.F. Rambaldi  
L. Mansi

## A new hypothesis for the bone marrow edema pathogenesis during transient osteoporosis

Received: 28 February 2006  
Accepted: 1 November 2006  
Published online: 18 December 2006

G. Negri (✉) • S. Grassi  
Department of Orthopaedics and  
Traumatology  
Ospedale Evangelico Villa Betania  
Via Argine 604, Naples, Italy  
E-mail: gnegri@fastwebnet.it

M. Zappia • S. Cappabianca  
Department of Diagnostic Imaging  
Second University of Naples  
Naples, Italy

P.F. Rambaldi • L. Mansi  
Department of Nuclear Medicine  
Second University of Naples  
Naples, Italy

**Abstract** Transient osteoporosis is an infrequent condition of uncertain etiology with pain, limited range of motion and radiographic evidence of osteoporosis affecting one or more joints. It is self-limited, reversible and can involve only the hip (transient osteoporosis of the hip, TOH) or, less frequently, one or more joints contemporaneously or at different times (regional migratory osteoporosis, RMO). We studied four men with transient osteoporosis, including two with TOH and two with RMO. All patients underwent a standard radiographic work-up of the affected joints, arteriovenous Doppler US,

computed tomography, magnetic resonance imaging (MRI) and three-phase bone scanning. In all patients, symptoms were related to bone marrow edema demonstrated at MRI and to a transitory regional arterial hyperflow observed at the early scintigraphic analysis. On the basis of our observations, we hypothesize that regional arterial hyperflow may be the cause of the bone marrow edema and therefore of the transient osteoporosis.

**Key words** Arterial hyperflow • Bone marrow edema • Regional migratory osteoporosis • Transient osteoporosis

### Introduction

Transient osteoporosis is an infrequent condition of uncertain etiology, with pain, limited range of motion and radiographic evidence of osteoporosis affecting one or more joints. It is self-limited and reversible. Transient osteoporosis can involve only the hip (transient osteoporosis of the hip, TOH) or, less frequently, one or more joints contemporaneously or at different times (regional migratory osteoporosis, RMO) [1–6].

Bone marrow edema is the main feature of this disease [7–11]. In an attempt to explain a cause for bone marrow edema, Takatori et al. [12] suggested that a reversible circulatory disturbance probably takes place in the bone marrow of the femoral head. Other authors [13, 14] consider TOH to be an early phase of avascular necrosis (AVN) that develops into complete AVN or regresses spontaneously.

Hofmann et al. [11] proposed that the etiology is related to a disturbance in venous outflow. Salomon [15] suggested that it is important to recognize the difference between bone marrow edema caused by a hypervascular disorder or by an ischemic disorder.

We used diagnostic imaging to investigate the role of regional circulatory disturbances in the etiology of transient osteoporosis, in a group of 4 men with TOH and RMO.

### Materials and methods

Between 2000 and 2004, the study enrolled patients with transient osteoporosis and intense joint pain during weight-bearing without a history of recent trauma or infection. All patients gave informed consent prior to their inclusion in the study.

Each patient underwent clinical examination. We obtained standard anteroposterior and lateral projections of the diseased joints with comparative examination of the healthy contralateral joint. Moreover, we performed computed tomography (Somatom HiQ; Siemens, Erlangen), magnetic resonance imaging (Magnetom SP42E; Siemens, Erlangen), bone scanning (Orbiter 75; Siemens, Erlangen) and arteriovenous color Doppler ultrasonography (Ansaldo-Hitachi 580).

At magnetic resonance imaging (MRI) we obtained T1-weighted spin echo images (TR, 500 ms; TE, 15 ms) in the three standard planes in addition to a sequence of spoiled gradient echo T2-weighted images (TR, 480 ms; TE, 18 ms; flip angle, 25°). Bone scans were obtained using a three-phase technique. Each patient was positioned supine under a large field gamma camera. An intravenous bolus of Tc99m-methylene diphosphonate (MDP, 555 MBq) was injected. During the vascular phase, we acquired 120 one-second frames of the affected joint, compared with the contralateral joint. Blood pool anteroposterior spot images were acquired after 5 minutes of the pathological joint. Whole body scan was performed after three hours to evaluate the osteoblastic activity phase; at this time, a spot image of the affected joint was also obtained. In patients with RMO, blood pool and 3-hour spot images were also obtained of the previously involved sites to evaluate the clinical course. One week after bone scanning, we performed angioscintigraphy with 555 MBq Tc99m albumin (Sorin Biomedica, Saluggia, Italy). All patients underwent arteriovenous Doppler ultrasonography (US) of the lower limbs.

The patients were managed by partially discharging the joint and by active mobilization without load. When symptoms resolved, we allowed full loading.

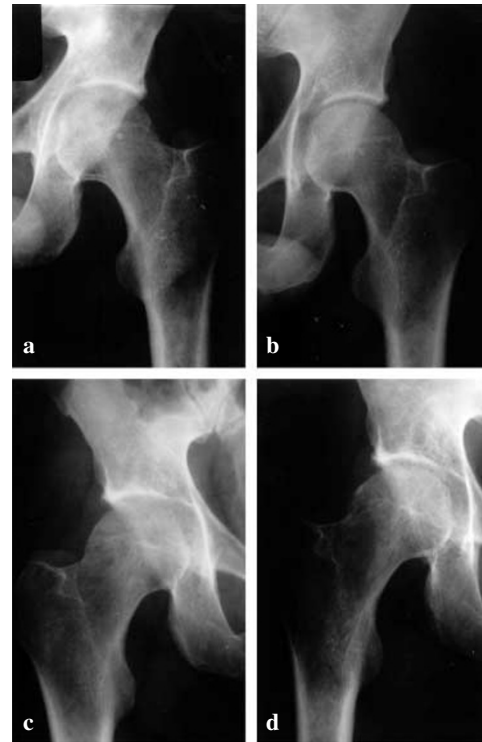
The study was conducted according to the principles of the Declaration of Helsinki and it was approved by the Ethical Committee at Second University of Naples.

## Results

The study enrolled 4 men with transient osteoporosis, including 2 with TOH and 2 with RMO (Table 1). The typical joint

nt pain lasted from 3 to 7 months (mean, 5). In all patients the disease led to no consequences. The two patients with RMO also had involvement of other joints of the lower limbs.

Radiographic exams were unremarkable within the first 15 days of clinical onset. These, however, showed osteoporosis about one month after symptoms' onset (Fig. 1a).

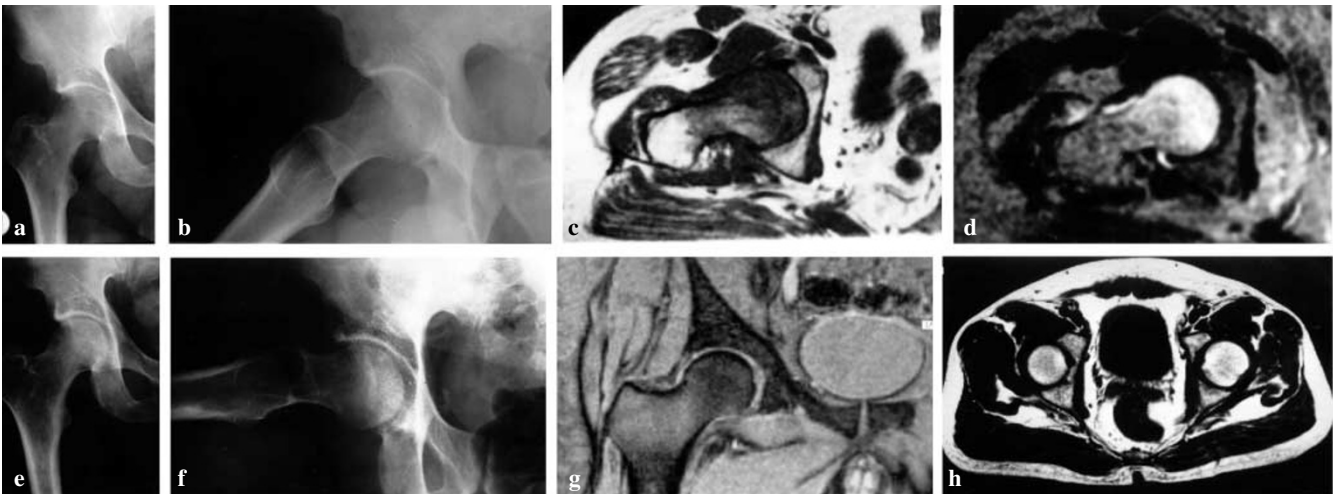


**Fig. 1a-d Case 1.** **a** One month after the onset of pain in the left hip, the radiograph shows moderate, diffuse osteoporosis. **b** Seven months later, restoration of bone density to near normal is evident. **c** Two months later, the patient complained of pain in the right hip. Right hip radiograph done at 3 weeks shows patchy rarefaction of bone throughout the proximal femur. **d** Two months after resolution of symptoms, radiograph shows nearly normal bone density

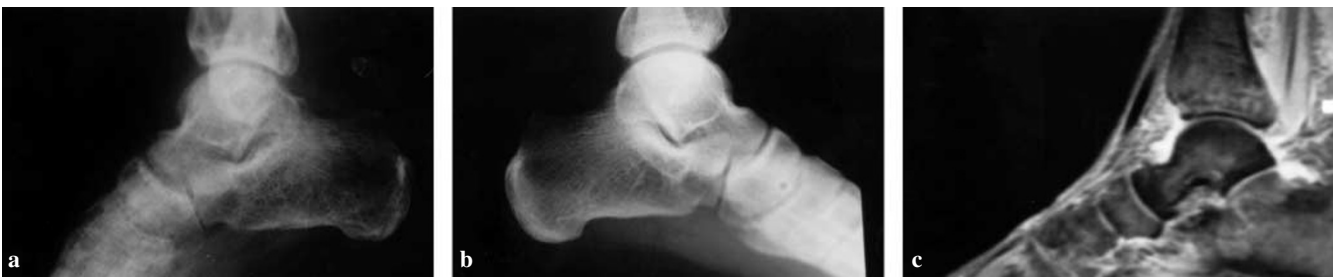**Table 1** Clinical characteristics of 4 men with transient osteoporosis

Patient	Age, years	Pathology	Affected joints	Duration of symptoms, months	Delay in onset between affected joints, months
1	35	TOH	Hip, left Hip, right	7 5	2 -
2	41	RMO	Knee, left Ankle, left	7 3	1 -
3	47	RMO	Hip, right Ankle, right Ankle left	6 4 3	1 4 -
4	48	TOH	Hip, left	4	-

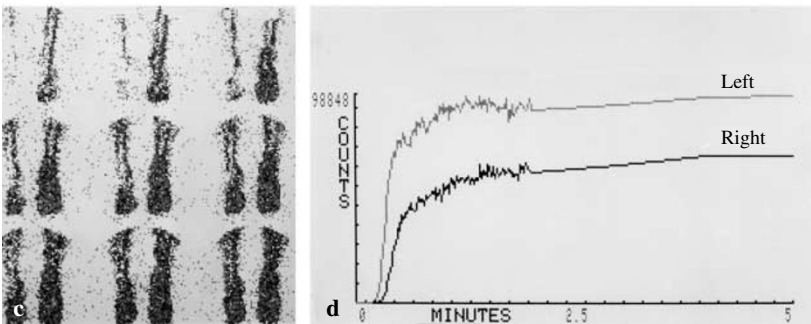
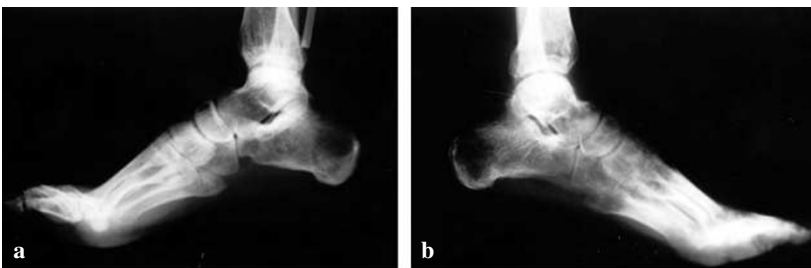TOH, transient osteoporosis of the hip; RMO, regional migratory osteoporosis



**Fig. 2a-h** Case 3. **a, b** Two months after the onset of pain in the right hip, anteroposterior and lateral radiographs show loss of radiodensity in the proximal femur, with indistinct margins of the femoral head. **c** At the same time, T1-weighted MR image shows irregular areas of decreased signal intensity in the head and neck of the right femur. **d** T2-weighted MR image in the same plane shows irregularly high signal intensity surrounding the femoral head and neck. **e, f** After six months, right hip radiographs reveal a nearly normal bone density. Margins are distinct. The patient no longer complained of pain. **g, h** T1- and T2-weighted MR images show normal signal intensity of the left hip



**Fig. 3a-c** Case 3. **a** One month after healing of the right hip, the patient complained of pain in the right ankle. Right ankle radiograph shows a marked loss of bone density. **b** Left ankle radiograph. **c** T1-weighted MR image showed irregular areas of decreased signal intensity in the talus of the right foot



**Fig. 4a-d** Case 3. **a, b** Four months after healing of the right ankle, the patient complained of progressive pain in the left ankle. After one month, radiographs show osteoporosis involving the left ankle. **c** Tc99m-albumin bone scan: vascular phase, one-second frames. Increased flow at the left foot. **d** Time/activity curves demonstrated increased arterial flow in the left foot

All cases presented an osteoporotic rarefaction of the joint ends (Figs. 2a, 3a, 4a). The profiles appeared hazy and difficult to define. The joint space remained constant. Demineralization increased progressively, and peaked two months after symptomatology onset. At the fifth or sixth month, remineralization was evident (Fig. 1b, 2e). After twelve months, the radiographic outline was normal. Computed tomograms also showed reduced bone density and confirmed the standard radiographic evidence (data not shown).

MRI examinations were always positive, even when carried out shortly after the onset of pain. There was a wide area at the joint ends which was difficult to define. The signal intensity on T1-weighted images was decreased with high intensity on T2-weighted images (Figs. 2c, 2d, 3c). Our opinion is that it represents bone marrow edema. It is worth noting that in the hip joint the acetabulum was not affected while the femur was altered from the head to the neck and in the trochanteric region. The results of the examination were normal at the fifth month. This corresponded to the termination of pain.

At three-phase bone scanning with Tc99m-MDP, carried out systematically at the first sign of illness, we noted an asymmetrical flow and distribution pattern of the tracer during the vascular phase with hyperflow and volume increase on the diseased side (Fig. 5). Three-hour images showed an accumulation of tracer according to increased osteoblastic activity (Fig. 5c).

Bone scanning was repeated after disappearance of pain (Fig. 6). Symmetrical flow and blood pool activity at the

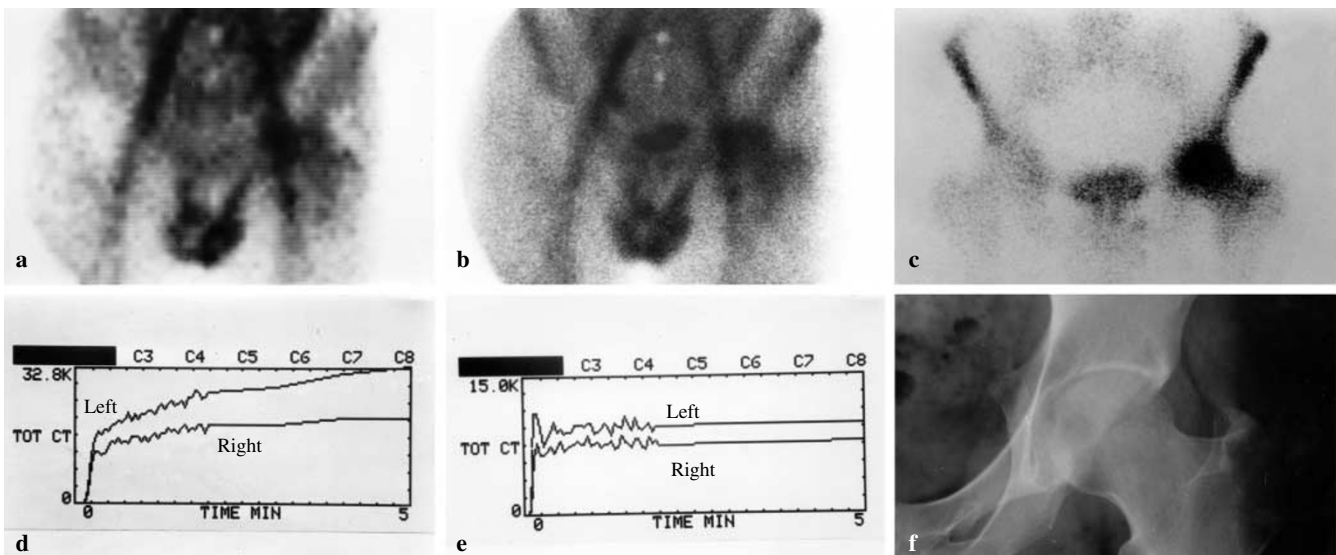
level of the diseased joint were observed, indicating normalized blood flow. However, 3-hour images demonstrated the persistence of an intense uptake in the same area, related to the persistence of increased osteoblastic activity (Fig. 6c).

In the two patients with RMO, images of the previously involved sites were normal in blood pool phase but showed increased activity on three-hour images (data not shown).

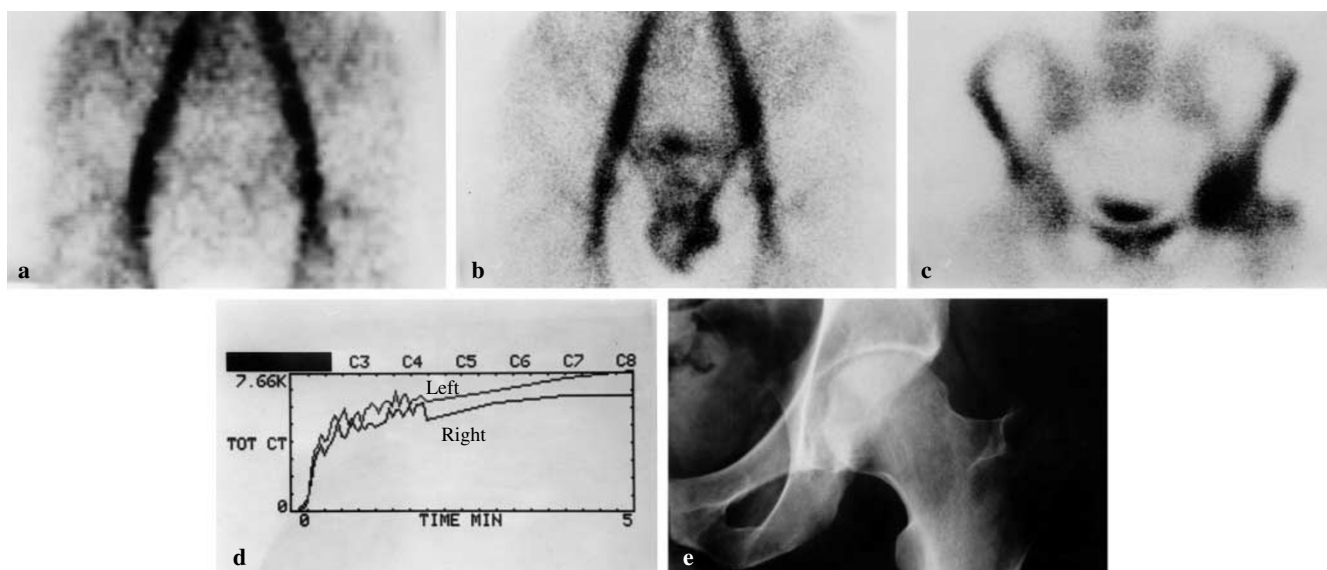
To better define these data, we also carried out angiography using Tc99m-albumin in all patients at the onset and at the end of the disease to confirm that the tracer's distribution at the diseased side was related to an increase in arterial blood flow. Tc99m-albumin, unlike Tc99m-MDP, does not diffuse and it does not bind to the bone tissue, therefore representing a reliable marker of the blood flow and pooling. Our data confirmed regional arterial hyperflow in the vascular phase, and an increased tracer distribution on blood pool images (Figs. 4c, 5e).

Venous and arterial Doppler US examinations of the lower limbs excluded vascular disease.

Comparison of how symptoms progressed with the results of the different diagnostic imaging exams showed that MRI and bone scanning are the most effective tests for an early diagnosis since positive results appeared at the onset of clinical symptomatology. MRI examinations rapidly turned to normal at the end of pain. The 3-hour images of the bone scans turned to normal less rapidly. Radiographs and computed tomograms gave positive results later and slowly turned to normal as the bone remineralized.



**Fig. 5a-f** Case 4. **a, b** Three-phase bone scanning using Tc99m-MDP performed 1 week after the onset of pain in the left hip. **a** Early image. **b** Blood pool image shows hyperemia in the region of the left hip. **c** Three-hour image shows an increased uptake in the left hip. **d** Time/activity curves demonstrate increased arterial flow at the left hip. **e** Tc99m-albumin performed five days later: time/activity curves demonstrate increased arterial flow at the left hip. **f** One month after the onset of pain, radiograph shows generalized and spotty demineralization



**Fig. 6a-e** Case 4. Three-phase bone scanning using Tc99m-MDP, at pain termination. Angiographic phase one (a) and blood pool image (b) are normal. c Three-hour image still shows increased uptake in the left hip. d Normal time/activity curves. e Radiograph taken one month later shows near normal bone density

## Discussion

While transient osteoporosis was initially discovered in pregnant women during the third trimester of pregnancy [5, 16, 17], it can affect both sexes, from late adolescence onward. A painful clinical symptomatology affects the joint, mostly the hip, with no apparent cause [4, 18–20]. After a gradual onset, the pain continues for several weeks and, at the same time, movement is impeded. Pain reduces or ceases at rest. Muscle hypotrophy and slight joint swelling may occur. In a few weeks, radiographs show a pattern identical to that of joint osteoporosis. Osteoporosis develops, reaches a peak in 6–12 months, and slowly regresses. In the migratory form (RMO), multiple joints are involved at the same time or, more often, at successive stages [2, 21, 22]. The etiology of TOH is unclear. Viral, inflammatory, metabolic and hormonal factors have been excluded. A transient ischemic insult to the bone may be responsible for transient osteoporosis [6]. Blood chemistry values are usually normal and synovial liquid is sterile. Histological examination may show areas of osteoporosis and insignificant inflammatory changes [5, 17, 18] or bone edema with necrotic and reparative processes [11].

Transient osteoporosis can be easily distinguished from several other diseases. During certain phases of the disease, a differential diagnosis between TOH and AVN is however possible through the use of MRI and bone scanning [5, 11, 23, 24]. In patients with TOH, MRI shows areas of weak signal on T1-weighted images and hyperintensity on T2-weighted images. These abnormalities correspond to an

increase in water content in the bone marrow. The presence of bone marrow edema has led some authors to consider TOH as a transient condition which can either lead to AVN of the hip or disappear spontaneously. As a result, the definitions of “transient marrow edema syndrome” [7], “transient osteoporosis” [1, 4, 12] and lastly “bone-marrow edema syndrome” [11] have been proposed.

Causes of the bone marrow edema in transient osteoporosis are unclear. Some authors suggested that this is a disturbance of the venous outflow [11]. Other authors proposed a distinction between hypervascular and ischemic disorders at the onset of the edema [13].

Our study using Tc99m-MDP and Tc99m-albumin scanning confirmed regional arterial hyperflow in the vascular phase. This is concurrent with an increase in the blood pool in the early phase of the disease. We demonstrated that bone marrow edema is a consequence of arterial hyperflow, although we cannot exclude a concomitant venous outflow disorder. The spontaneous resolution of this regional arterial hyperflow, with resolution of bone marrow edema on MR images, coincides with the disappearance of pain. Successively, full weight bearing permits remineralization of the affected joint and termination of the illness.

It has to be pointed out that blood flow and volume and osteoblastic activity do not present overlapping behaviors at bone scanning. While the increased flow and volume disappear with symptoms, high uptake on the 3-hour scans, expressing high osteoblastic activity, is present also after disappearance of pain.

Since TOH is self-limited and is of brief duration, surgical core-decompression is probably not indicated.

In conclusion, our data suggest that temporary arterial hyperflow may contribute to the transitory bone marrow edema

observed in transient osteoporosis. Further studies are needed to elucidate the cause of arterial hyperflow in this disease.

## References

1. Toms AP, Marshall TJ, Becker E, Donell ST, Lobo-Muller EM, Barker T (2005) Regional migratory osteoporosis: a review illustrated by five cases. *Clin Radiol* 60:425–438
2. Langlosh ND, Hunder GG, Riggs BL, Kelly PJ (1973) Transient painful osteoporosis of the lower extremities. *J Bone Joint Surg Am* 55:1188–1196
3. Resnick D, Niwayama G (1985) *Patologia e diagnostica dell'apparato locomotore*, vol. 3. Verduci, Rome, pp 1665–1666
4. Bloem J (1988) Transient osteoporosis of the hip: MR imaging. *Radiology* 167:753–755
5. Brodell JD, Burns JE Jr, Heiple KG (1989) Transient osteoporosis of the hip of pregnancy. Two cases complicated by pathological fracture. *J Bone Joint Surg Am* 71:1252–1257
6. Guerra JJ, Steinberg ME (1995) Distinguishing transient osteoporosis from avascular necrosis of the hip. *Current concepts review. J Bone Joint Surg Am* 77:616–624
7. Wilson AJ, Murphy WA, Hardy DC, Totty WG (1988) Transient osteoporosis: transient bone marrow edema? *Radiology* 167:757–760
8. Moosikasuwan JB, Miller TT, Math K, Shultz E (2004) Shifting bone marrow edema of the knee. *Skeletal Radiol* 33:380–385
9. Grimm J, Higer HP, Benning R, Meairs S (1991) MRI of transient osteoporosis of the hip. *Arch Orthop Trauma Surg* 110:98–102
10. Urbanski SR, de Lange EE, Eschenroeder HC (1991) Magnetic resonance imaging of transient osteoporosis of the hip. *J Bone Joint Surg Am* 73:451–455
11. Hofmann S, Engel A, Neuhold A, Leder K, Kramer J, Plenk I Jr (1993) Bone-marrow edema syndrome and transient osteoporosis of the hip. *J Bone Joint Surg Br* 75:210–216
12. Takatori Y, Takashi K, Ninomiya S, Nakamura T, Okutsu I, Morihide K (1991) Transient osteoporosis of the hip. *Clin Orthop Relat Res* 271:190–194
13. Mitchell DG, Steinberg ME, Dalinka MK, Rao VM, Fallon M (1989) Magnetic resonance imaging of the ischemic hip. Alteration within the osteonecrotic, viable, and reactive zones. *Clin Orthop Relat Res* 244:60–70
14. Turner DA, Templetom AC, Selzer PM, Rosenberg AG, Petasnick JP (1989) Femoral capital osteonecrosis: MR finding of diffuse marrow abnormalities without focal lesions. *Radiology* 171:135–140
15. Salomon L (1993) Bone-marrow edema syndrome. *J Bone Joint Surg Br* 75:175–176
16. Curtiss PR, Kincaid WE (1959) Transitory demineralization of the hip in pregnancy. *J Bone Joint Surg Am* 41:1327–1333
17. Beaulieu JG, Razzano CD, Levine RB (1976) Transient osteoporosis of the hip in pregnancy. Review of the literature and a case report. *Clin Orthop Relat Res* 15:165–168
18. Kaplan SS, Stegman CJ (1985) Transient osteoporosis of the hip. *J Bone Joint Surg Am* 67:490–493
19. Keys GW, Walters J (1987) Idiopathic transient osteoporosis of the hip: brief report. *J Bone Joint Surg Br* 69:773–774
20. Shifrin LZ, Reis ND, Zinman H, Beisser ML (1987) Idiopathic transient osteoporosis of the hip. *J Bone Joint Surg Br* 69:769–773
21. Brambleth KW, Killian JT, Nasca RI, Daniel WW (1987) Transient osteoporosis. *Clin Orthop Relat Res* 222:197–202
22. Horiuchi K, Shiraga N, Fujita N, Yamaguchi M, Yabe H (2004) Regional migratory osteoporosis: a case report. *J Orthop Sci* 9:178–181
23. Crespo E, Sala D, Crespo R, Silvestre A (2001) Transient osteoporosis. *Acta Orthop Belg* 67:330–337
24. Kim SM, Desai AG, Krakovitz M, Intenzo CM, Park CH (1989) Scintigraphic evaluation of regional migratory osteoporosis. *Clin Nucl Med* 14:36–39