

Role of valgus osteotomy and fixation with dynamic hip screw and 120° double angle barrel plate in the management of neglected and ununited femoral neck fracture in young patients

Abdul Qayyum Khan · Mohammad Shahnawaz Khan ·
Mohammed Khalid Anwar Sherwani ·
Rahul Agarwal

Received: 5 October 2008 / Accepted: 3 March 2009 / Published online: 2 April 2009
© Springer-Verlag 2009

Abstract

Background Head preservation is the mainstay of management in younger patients with neglected or ununited intracapsular fracture neck of femur. Very few reports have dealt with the results of valgus intertrochanteric osteotomy and fixation with dynamic hip screw in such cases. In this prospective study, we have tried to evaluate the role of valgus osteotomy and fixation with dynamic hip screw and 120° double angle barrel plate in neglected or ununited intracapsular fracture neck of femur in patients below 60 years of age and whose time since injury is equal to or more than 3 weeks.

Materials and methods We treated 16 such cases with valgus intertrochanteric osteotomy and fixation achieved with dynamic hip screw and 120° double angle barrel plate, with mean age of 36.4 years. The cases were evaluated radiologically and clinically at a mean of 19 months.

Results In 14 of the 16 patients, the fracture went on to satisfactory union after an average of 14.7 weeks (10–26.7 weeks). The average Harris hip score increased from 66.6 points (range 55–75 points) before surgery to 88 points (range 75–95 points). All the patients with united fractures were able to sit cross-legged, squat and do one-leg stance. Pain and limitation of motion improved remarkably. Two patients had unfavourable outcome; both had cut-through of the implant, out of the head.

Conclusions Valgus intertrochanteric osteotomy is a very cheap and effective procedure to achieve union in neglected and ununited fracture neck femur in young patients. We propose fixation with dynamic hip screw and

120° double angle barrel plate as it provides additional compression and, with valgus osteotomy, improved stability of internal fixation, with few complications.

Keywords Neglected/ununited fracture neck femur · Valgus osteotomy · Dynamic hip screw and 120° double angle barrel plate

Introduction

Intracapsular fracture neck of femur is one of the commonly encountered injuries in orthopaedics. It is more common in elderly individuals [1]. Only 2–3% of these occur in patients younger than 50 years [2]. However, the increase in high-energy trauma has contributed to the increased incidence of fracture neck of femur in younger patients. Young and active patients are generally treated by anatomical reduction and internal fixation as soon as possible. Maninger et al. [3] reported a lower incidence of femoral head collapse when reduction and internal fixation was carried out within 6 h of injury. However, it remains a major problem in developing countries where the patient reports many weeks or months after the fracture because of poverty, ignorance, lack of facilities and faith in traditional bone-setters [4–7]. Despite improvements in the techniques of surgery and internal fixation devices, non-union is still reported in one-third of cases of femoral neck fracture with displacement [8]. Among the head-retaining procedures in such circumstances, various procedures such as fixation with muscle pedicle bone grafting, internal fixation with vascularised or free fibular grafting and valgus osteotomy and internal fixation are advocated, showing variable results; no one technique has proved entirely satisfactory [9, 10].

A. Q. Khan (✉) · M. S. Khan · M. K. A. Sherwani ·
R. Agarwal
Department of Orthopaedic Surgery, Jawaharlal Nehru Medical
College, Aligarh Muslim University, Aligarh 202002, India
e-mail: drabdulqayyum@rediffmail.com

Valgus intertrochanteric osteotomy alters the biomechanical environment of the fracture site and restores limb length. Very few reports have dealt with the results of this procedure internally fixed with dynamic hip screw and double angle barrel plate.

We conducted a prospective study at our institution to evaluate the clinical and radiographical results of valgus intertrochanteric osteotomy and fixation by dynamic hip screw and 120° double angle barrel plate in the treatment of neglected and ununited femoral neck fractures in patients less than 60 years old.

Materials and methods

Between January 2004 and July 2007, we performed valgus intertrochanteric osteotomies for neglected and ununited femoral neck fractures in 16 consecutive patients with mean age of 36.4 years (range 20–60 years, Table 1).

Inclusion criteria

- (a) Patients less than 60 years of age with fracture neck of femur of more than or equal to 3 weeks since injury.
- (b) Patients less than 60 years of age with failed primary fixation (non-union with varus collapse).

Exclusion criteria

Elderly patients (>60 years of age) and patients who had changes of avascular necrosis (AVN) on plain radiography or magnetic resonance imaging (MRI) and significant resorption of femoral neck with proximal fragment less than 2.5 cm were excluded from the study. There were 12 males and 4 females with an equal number of right and left hip affected (8 each). Delay in presentation ranged from 3 to 76 weeks (mean 31 weeks). The mechanism of injury was road-traffic accident in seven patients, fall from height in six and slipping onto ground in three. All patients were in good health before the fracture and walking without any aid, except one who had Parkinsonism. All fractures were displaced (Garden grade 3 and 4) without any evidence of avascular necrosis ruled out by preoperative plain radiograph or MRI scan. Four patients had undergone previous surgery. All four had fixation with cannulated cancellous screws and two had fibular strut autografting also with varus collapse at fracture site.

Preoperatively, all patients complained of pain and limitation of hip motion and were unable to walk without support. Prior to osteotomy, average neck-shaft angle was 102° (80–120°), with average limb shortening of 1.5 cm (1.0–2.8 cm). The greater trochanter was upridding in seven

cases and needed skeletal traction before surgery (7–10 days). None of these had evidence of AVN on plain radiograph or MRI. One patient was known to be diabetic, while one had Parkinsonism. All the osteotomies were fixed by dynamic hip screw and 120° double angle barrel plate. The patients had minimum follow-up of 11 months and a maximum of 36 months (mean 19 months).

Surgical technique

Preoperative planning

Calculation of wedge angle

Fracture plane measured off the horizontal plane (line touching the roofs of acetabulum) is the Pauwels' angle or "shear angle". Pauwels' optimal angle is usually between 20° and 25° [11]. The calculation is derived from the fact that for any given stance the body weight is projected at the head of femur at an angle of 160°, according to Pauwels; hence the compressive force will be at a right angle to this, i.e., $180^\circ - 160^\circ = 20^\circ$.

Osteotomy angle or wedge angle is designed to produce a final desired fracture plane angle of less than 30°. According to Pauwels' principles a non-union will come under compression force when it forms an angle of 30° or less. A final desired fracture plane angle of 30° was set for all the patients.

Therefore angle of correction or wedge angle was calculated as:

Wedge angle (osteotomy angle)

$$= \text{Shear angle} - \text{Postop. desired angle (30}^\circ\text{)}.$$

Calculation of pin insertion angle

Pin insertion angle is the angle created between the borders of the pin within the femoral neck (which is placed at the centre of femoral head at the start of operation) and lateral femoral cortex. The sliding hip screw is placed towards the centre of the head at the predetermined pin insertion angle.

$$\text{Pin insertion angle} = \text{Implant angle} - \text{Osteotomy angle}.$$

In all patients, surgery was performed on a fracture table with fluoroscopic control, with the patient in supine position. The fracture site was not exposed in any patient. The failed implant, if present, was removed; the dynamic hip screw was inserted (Fig. 1a). All patients underwent intertrochanteric osteotomy as described by Pauwels [11] and modified by Mueller [12]. The procedure included an intertrochanteric osteotomy at the upper border of the lesser trochanter, removal of a lateral wedge, subsequent valgisation, lateral displacement of the distal fragment and internal fixation by a 120° double angle barrel plate

Table 1 Patient information

Patient no.	Age	Sex	Time from injury to osteotomy (weeks)	Previous treatment	Preoperative neck shaft angle (degrees)	Postoperative neck shaft angle (degrees)	Preoperative Pauwels' angle (degrees)	Postoperative Pauwels' angle (degrees)
1	35	M	16	None	120	135	60	42
2	60	M	34	None	88	128	45	36
3	51	F	68	CCS	115	140	54	36
4	46	M	6	None	120	145	42	34
5	38	M	21	None	116	136	46	32
6	20	M	3	None	95	120	44	36
7	40	M	76	CCS with fibular grafting	98	125	46	30
8	32	F	72	CCS	100	134	54	32
9	25	M	26	None	80	130	48	34
10	33	M	18	None	92	132	56	40
11	32	M	38	None	100	135	70	42
12	25	M	8	None	95	124	64	30
13	41	F	10	None	96	126	46	36
14	52	F	63	CCS with fibular grafting	110	136	40	26
15	32	M	15	None	100	126	38	30
16	21	M	22	None	110	138	65	44

Patient no.	Preoperatively limb length shortening (cm)	Postoperatively limb length discrepancy (cm)	Preoperative Harris hip score	Postoperative Harris hip score	Outcome	Complications
1	2.5	1.8	60	92	Excellent	
2 ^a	1.0	1.0	55	75	Poor	Cut out of implant
3	1.0	1.5 ^c	75	92	Excellent	
4	1.0	1.5 ^c	68	88	Excellent	
5	2.5	1.4	64	91	Excellent	
6	1.0	0.5	64	90	Excellent	
7	1.0	1.0	72	86	Excellent	
8	1.0	0.0	70	95	Excellent	
9	1.3	0.6	68	90	Excellent	
10	1.0	1.5 ^c	65	93	Excellent	
11	2.8	1.6	70	84	Excellent	
12	2.0	1.5	65	88	Excellent	
13 ^b	1.0	1.4 ^c	60	76	Poor	Cut out of implant
14	1.5	1.0	68	95	Excellent	
15	1.4	1.5 ^c	70	90	Excellent	
16	2.0	1.5	72	86	Excellent	

M male, *F* female, *CCS* cannulated cancellous screws

^a Suffered from Parkinsonism

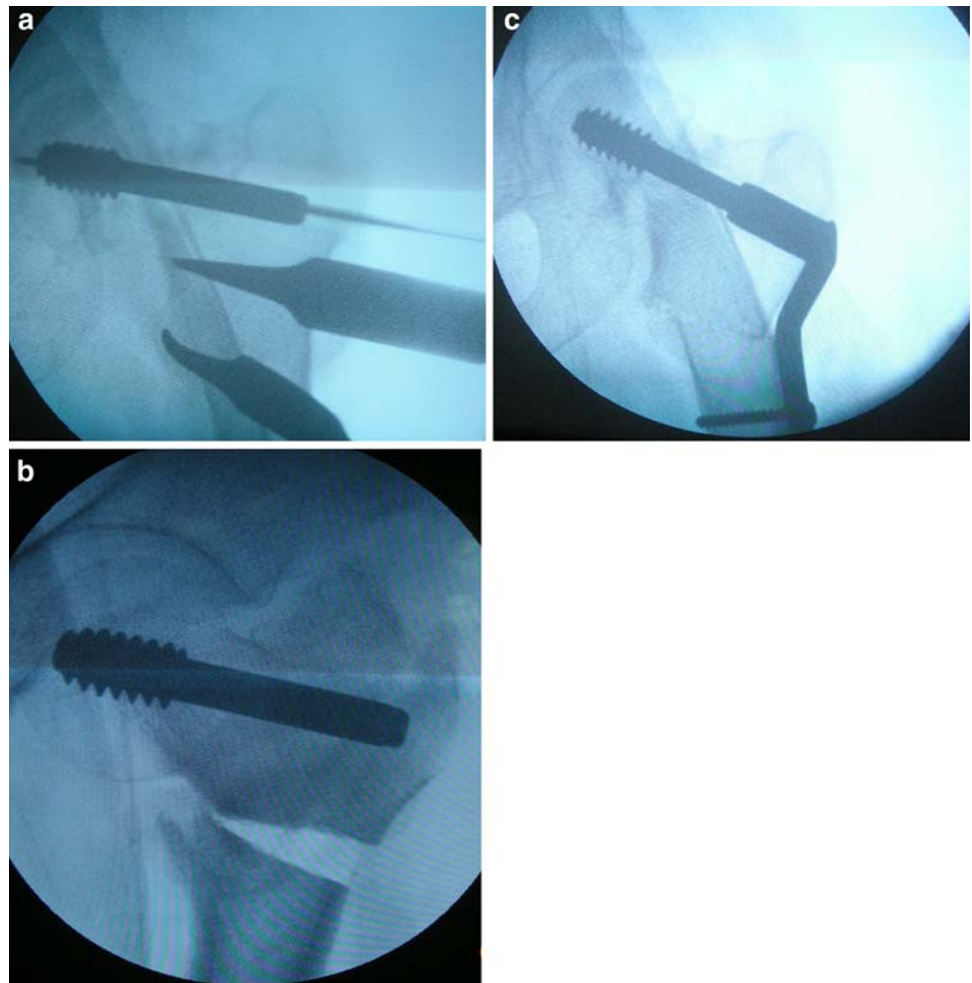
^b Suffered from diabetes mellitus

^c Lengthening occurred

(Fig. 1b, c). Triple reaming, tapping and hip screw insertion was performed under fluoroscopic control. A temporary wire was placed in the femoral head after the placement of guide wire for hip screw insertion in all patients, to prevent

rotation, as this rotation of femoral head might further damage the precarious blood supply to the femoral head and increase the risk of development of AVN. No bone grafting procedure was done in any of the patients.

Fig. 1 **a** Placement of dynamic hip screw over guide wire. **b** Intertrochanteric osteotomy done just above the lesser trochanter and pre-calculated wedge resected. **c** Gap after osteotomy reduced by fixation of 120° double angle barrel plate



Knee and ankle physiotherapy were started next day and the patients were mobilised with crutches non-weight-bearing from third postoperative day. The patients were evaluated radiographically in an outpatient clinic at 8 weeks postoperatively and further at 6-week intervals until union was achieved, when full weight-bearing was started. Radiographic union was defined by absence of a fracture line and appearance of trabeculae across the fracture site (Fig. 2a–c).

Ethical considerations

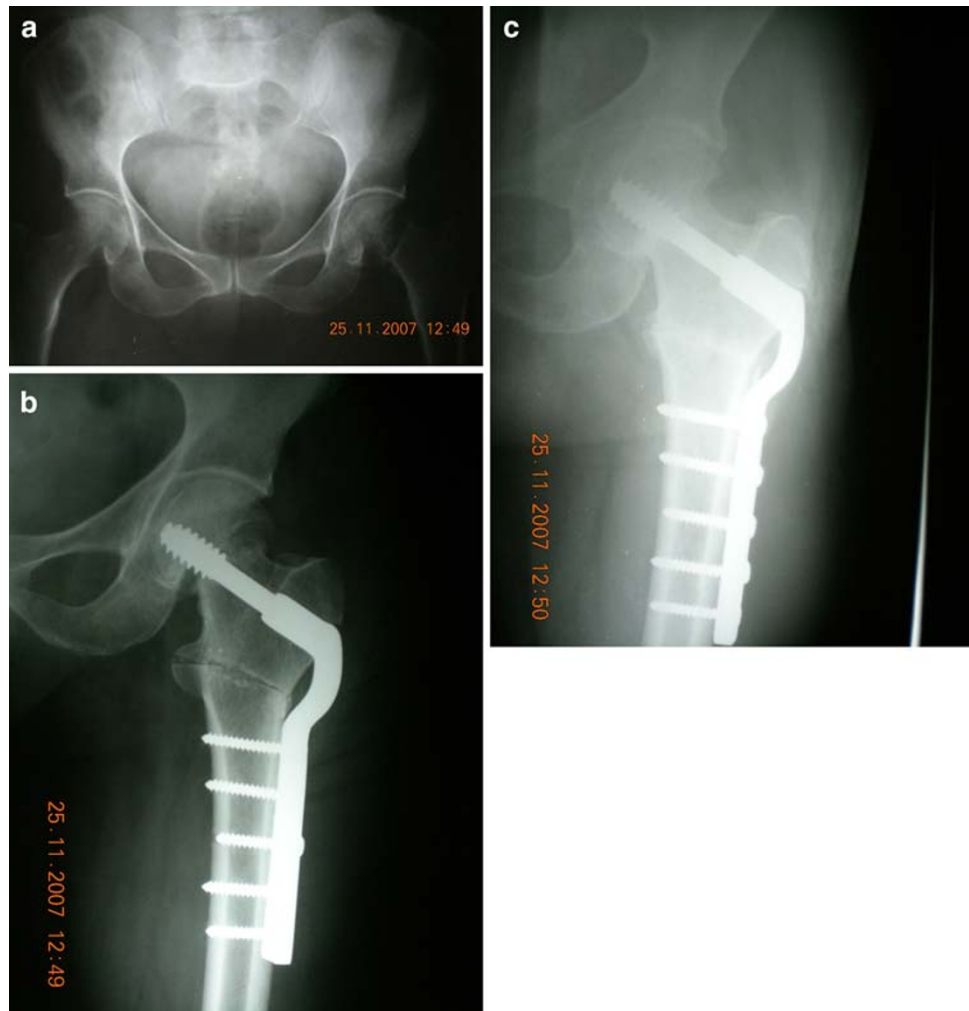Informed consent was taken from the patients prior to operation and for inclusion in the study. The study was performed according to the Declaration of Helsinki, and the Institutional Ethical Board approved it.

Results

All patients were monitored for an average of 19 months (range 11–36 months). The average Harris hip score

increased from 66.6 points (range 55–75 points) before surgery to 88 points (range 75–95 points). Excellent results were achieved for 14 patients; two patients had poor results due to cut-out of implant. In 14 of the 16 patients, the fracture went on to satisfactory union after an average of 14.7 weeks (10–26.7 weeks). No patient was lost to follow-up. The average preoperative neck-shaft angle of 102° (range 80–120°) increased to 132° (range 120–145°) after surgery. The average limb length discrepancy postoperatively was 1.2 cm (range 0–1.6 cm). Two patients had unfavourable outcome, due to cut-through of the implant, out of the head after 8 weeks of surgery. Of these two patients one was diabetic and another was suffering from Parkinsonism, and both had moderately osteoporosed proximal fragment. Implant removal and hemireplacement arthroplasty with bipolar prosthesis was done in both of them and they did well in the final follow-up. No patient had any serious immediate postoperative complication such as deep infection or deep vein thrombosis. No patient had coxa vara, defined as neck shaft angle less than 120°, and osteotomy site united in all patients at an average time of 10.3 weeks (range 8–12 weeks). All the patients with

Fig. 2 **a** Radiograph showing non-union fracture neck of femur (21 weeks old). **b** Immediate postoperative radiograph showing more horizontal fracture line with valgus osteotomy fixed by dynamic hip screw and 120° double angle barrel plate. **c** Union achieved after 10 weeks of valgus osteotomy



united fractures were able to sit cross-legged, squat and do one-leg stance. Pain and limitation of motion improved remarkably, so that the majority of the patients did not have to use crutches at 6 months after operation.

Discussion

Non-union after femoral neck fracture is defined as lack of radiographic evidence of union 6 months after fracture. King [13], in 1939, in his comprehensive review of both recent and old case of fracture neck femur, emphasised that 3 weeks old can be arbitrarily called old and ununited, as it can be assumed that the head of the femur is devoid of its blood supply, has less chances of osseous union and that secondary changes are more probable than if operation were performed earlier. If the fracture neck of femur remains untreated for more than 3 weeks, internal fixation alone is likely to have high rate of non-union, as reported by Barnes et al. [1]; in their series on fractures of more than 1-week duration they had non-union rate as high as 50%.

The femoral neck fracture is probably the fracture for which there exists the larger number of methods of osteosynthesis. Internal fixation of femoral neck fracture is followed by certain incidence of fixation failure. Non-union may occur in one-third of patients, with higher rate in vertical or displaced fractures [14]. Number of methods of internal fixation when used alone have failed to achieve the desired end result. Osteoporosis directly influences degree of displacement and quality of internal fixation. The deficient bone stock and posterior comminution play a significant role in biological failure to unite the fracture. Age and sex of patient, osteoporosis, degree of displacement and quality of fracture reduction are the factors that have been found to affect the end result [15, 16]. The appropriate treatment for non-union of a femoral neck fracture depends on the age of the patient, his or her medical status, viability of the femoral head, size of the remnant femoral neck, osteoporosis, duration of the disease and finally the state of joint space. Considering the fact that the majority of patients with femoral neck fracture are over 60 years of age, have extreme osteoporosis and are poor

surgical candidates, it is better to replace the femoral neck with a femoral prosthesis or a total joint replacement. In the case of infection of the joint with non-union of the femoral neck, when it is not possible to do total joint replacement, it is better to perform resection arthroplasty (Girdlestone procedure). In patients younger than 55 years who are in good general medical condition, with no osteoporosis and with a reasonable size of femoral neck and normal joint space, it is desirable to preserve the femoral head, particularly if the patient's lifestyle and social and religious customs require squatting and sitting in a cross-legged position [17].

Treatment options for femoral neck non-union with preservation of the femoral head include refixation of the fracture, refixation and bone grafting, a pedicle graft to provide blood supply, or a valgus osteotomy with fixation. Cortical bone grafts have been associated with disimpaction or angulations of the head leading to failure [18]. The initially reported success of Meyer's procedure has not been reproduced in a large series and the procedure has been considered unreliable [19]. Arthrodesis has a high failure rate but, when successful, it leads to a functional hip. Different techniques of vascularised bone grafting have been introduced, often with excellent results [10, 20], but the usefulness of these techniques is limited because of donor-site morbidity and limb length discrepancy with residual varus deformity.

Pauwels recognised that non-union of femoral neck fracture would consolidate within few months if shearing force acting on non-union fracture site were transformed into compression forces [21]. Good results had been reported in femoral neck fracture treated with primary osteosynthesis and valgus intertrochanteric osteotomy [22, 23]. Marti et al. [23] reported 86% union in 50 patients at an average of 3.6 months, treated by this method alone. Twenty-two hips preoperatively had avascular necrosis, with three of these cases progressed to collapse, necessitating total hip replacement (THR). Anglen [24] reported results for a series of 13 patients, all of whose femoral neck fractures united. However, in two of these cases avascular necrosis developed later, requiring THR. In our study, follow-up did not reveal any avascular necrosis and subchondral collapse. Postoperatively we achieved an average fracture plane of 35° (26°–44°), although we aimed for fracture plane of less than 30°. This technique resulted in union in 14 of 16 patients, even though the final fracture plane was more than 30°, as the use of dynamic hip screw added compression at the fracture site.

In most of case series reported in literature on valgus osteotomy [23–25], blade plate fixation has been used, which is technically demanding. In internal fixation of valgus osteotomy by double angle blade plate, at times blade may displace the fracture fragments and minimal

change in the direction of blade may change the direction of plate anterior or posterior to the shaft of femur. Most orthopaedic surgeons are accustomed to the use of dynamic hip screw, which is commonly used in the treatment of intertrochanteric fractures, and is technically much simpler than blade plate fixation. In dynamic hip screw fixation, powered instruments could be used, which saves time and reduces blood loss. Also hammering required in blade plate fixation is avoided, with additional advantage of compression at fracture site.

We believe that valgus osteotomy acts as a biological stimulus for healing of these fractures, promoting osteogenesis as a result of conversion of shearing forces to compressive forces across the fracture site. The osteotomy is relatively easy to perform, cost effective, provides stability and often is definitive one-time surgery.

Valgus osteotomy and internal fixation with dynamic hip screw and 120° double angle barrel plate plays a twofold role: it converts the shearing forces into the compression forces by placing the fracture site perpendicular to the resultant of body weight forces; and it buttresses the head of femur from below to improve stability provided by the internal fixation [12]. Osteosynthesis with dynamic hip screw in its optimum position in the femoral head, supplemented by the buttressing effect of the distal osteotomy fragment, maintains coaptation and immobilisation of the fragments and provides a high degree of stability.

Following osteotomy, valgus orientation of the proximal femur decreases the lever arm and therefore increases contact pressure on the head. This may in turn lead to degenerative disease or progression of osteonecrosis [11]. Lengthening of acetabulotrochanteric distance occurs, which may stretch the abductor muscles and capsule, which would compromise muscle and capsule circulation [26]. Reaming to insert a lag screw may destroy intramedullary vascularity [27–29]. Progression of femoral head necrosis following osteotomy has been reported by many authors [19, 23, 24, 30] and radiographic signs of avascular necrosis in patients over 30 years of age was considered to be a contraindication for osteotomy by Walcher and Wiesinger [31].

So, keeping in mind the facts of above-mentioned studies, it seems that performing valgus osteotomy in a hip with changes of AVN may lead to progression of disease and a painful hip later on, and therefore we excluded these patients from our study.

Many authors have reported that preoperative presence of osteonecrosis is not a contraindication for osteotomy [12, 23, 24, 30, 32]. Catto [33] believed that a neck fracture can heal and a necrotic head can be vascularised, although the process requires prolonged, adequate fixation. Raaymakers et al. [34] have mentioned that “in the race between revascularisation and collapse, often

revascularisation is the winner”. However more studies are required to prove this notion.

In our present study, because of the delay in intervention and the young age of patients, Pauwels’ osteotomy was performed as the head-salvaging procedure. Union was achieved in 87.5% of our patients, which is quite good for any surgical intervention. Implant cut-out was the only significant complication that we encountered in our study. Both of these patients had other associated conditions (Parkinsonism and diabetes) and both had osteoporosed proximal fragment. Osteoporosis decreases the quality of internal fixation; hence patients with decreased bone stock should be considered for other alternative procedures. Among the united fractures, all were able to sit cross-legged, squat and stand on affected leg, which are needed in day-to-day life. This also is another advantage over the head-replacing procedure. Marti et al. [23] reported that collapse can occur 3–4 years later following osteotomy. Follow-up period of 3 years in our study was a limitation in this regard and longer follow-up is required for evaluation of collapse in femoral head. There is a criticism about the difficulty in performing THR in these patients, when required at a later stage. However, Marti et al. [23] reported no such problems. Kirby [35] stated that the standard prosthesis could be used for THRs in majority of the cases.

We conclude by stating that valgus osteotomy and fixation with dynamic hip screw and 120° double angle barrel plate has high success rate in young patients with neglected and ununited intracapsular fracture neck of femur as far as the union of fracture is concerned, and internal fixation with dynamic hip screw and 120° double angle barrel plate is technically simple, with additional advantage of compression at fracture site by hip screw.

Conflict of interest statement No financial grants have been received for the study. No other people or organisation is associated with the study to influence the work.

References

- Barnes JT, Brown JT, Garden RS, Nicoll EA (1976) Subcapital fractures of the femur: a prospective review. *J Bone Joint Surg* 58B:2–24
- Zetterberg C, Elmerson S, Andersson GBJ (1984) Epidemiology of hip fractures in Goteborg 1940–1983. *Clin Orthop* 191:43–52
- Maninger J, Kazar C, Fekete C et al (1989) Significance of urgent (within 6h) internal fixation in the management of fractures of the neck of the femur. *Injury* 20:101–105
- Barnes B, Dunovan K (1987) Functional outcomes after hip fracture. *Phys Ther* 67:1675–1679
- Huang CH (1986) Treatment of neglected femoral neck fractures in young adults. *Clin Orthop* 206:117–126
- Lifeso R, Young D (1990) The neglected hip fracture. *J Orthop Trauma* 4:287–292
- Nagi ON, Dhillon MS, Gill SS (1992) Fibular osteosynthesis for delayed type II and type III femoral neck fractures in children. *J Orthop Trauma* 6:306–313
- Banks HH (1974) Nonunion in fractures of the femoral neck. *Orthop Clin North Am* 5:865–885
- Jackson M, Learmonth ID (2002) The treatment of non union after intracapsular fracture of the proximal femur. *Clin Orthop* 399:119–128
- LeCroy CM, Rizzo M, Gunneson EE et al (2002) Free vascularised fibular bone grafting in the management of femoral neck non union in patients younger than fifty years. *J Orthop Trauma* 16:464–472
- Pauwels F (1976) *Biomechanics of the normal and diseased hip*. Springer, Berlin, pp 129–271
- Mueller ME (1999) The intertrochanteric osteotomy and pseudoarthrosis of the femoral neck. *Clin Orthop* 363:5–8
- King T (1939) Closed operation for intracapsular fracture of the neck of the femur. *Br J Surg* 26:721
- Lu-Yoa GL, Keller RB, Littenberg B, Wenliberg JE (1994) Outcomes after displaced fractures of the femoral neck. A meta-analysis of one hundred and six published reports. *J Bone Joint Surg Am* 76:15–23
- Garden RS (1964) Stability and union in subcapital fractures of the femur. *J Bone Joint Surg Br* 46:630–647
- Dalen N, Jacobson B (1986) Rarefied femoral neck trabecular patterns, fractures displacement and femoral head vitality in femoral neck fractures. *Clin Orthop* 207:97–98
- Hammer AJ (1992) Nonunion of subcapital femoral neck fractures. *J Orthop Trauma* 6:73–77
- Baksi DP (1986) Internal fixation of ununited femoral neck fracture combined with muscle-pedicle bone grafting. *J Bone Joint Surg Br* 68:239–245
- Zukerman JD, Koval KJ (1993) Hip trauma. In: Frimoyer JW (ed) *Orthopaedic knowledge update 4*. American Academy of Orthopaedic Surgeons, Rosemont, pp 525–538
- Nagi ON, Dhillon MS, Goni VG (1998) Open reduction, internal fixation and fibular autografting for neglected fracture of the femoral neck. *J Bone Joint Surg Br* 80-B:798–804
- Pauwels F (1935) *Der Schenkelhalsbruch ein mechanisches Problem: Grundlagen des Heilungsvorganges, Prognose and kausale Therapie*. Ferdinand Enke Verlag, Stuttgart
- Rinaldi E, Marengi P, Negri V (1984) Osteosynthesis with valgus osteotomy in the primary treatment of subcapital fractures of the neck of the femur. *Ital J Orthop Traumatol* 10(3):313–320
- Marti RK, Schuller HM, Raaymakers EL (1989) Intertrochanteric osteotomy for nonunion of the femoral neck. *J Bone Joint Surg Br* 71:782–787
- Anglen JO (1997) Intertrochanteric osteotomy for failed internal fixation of femoral neck fracture. *Clin Orthop* 341:175–182
- Zehi K, Bouguira A, Saadaoui F et al (2001) Valgus osteotomy in the treatment of pseudoarthrosis of the femoral neck. *Rev Chir Orthop Reparatrice Appar Mot* 87:562–568
- Frangakis EK (1966) Intracapsular fractures of the neck of the femur: factors influencing non-union and ischaemic necrosis. *J Bone Joint Surg Br* 48-B:17–30
- Brodetti A (1960) The blood supply of the femoral neck and head in relation to the damaging effects of nails and screws. *J Bone Joint Surg Br* 42-B:794–801
- Aginsky J, Reis ND (1980) The present state of medullary nailing of the femur: biomechanical limitations and problems of blood supply to the fracture due to reaming. *Injury* 11:190–196
- Braten M, Terjesen T, Svenningsen S, Kibbsgaard L (1990) Effect of medullary reaming on fracture healing: tibial osteotomies in rabbits. *Acta Orthop Scand* 61:327–329

30. Ballmer FT, Ballmer PM, Baumgartel F, Ganz R, Mast JW (1990) Pauwels osteotomy for nonunions of the femoral neck. *Orthop Clin North Am* 21:759–767
31. Walcher K, Wiesinger H (1983) Pauwels valgization osteotomy or alloplasty in pseudarthrosis of the femur neck. *Aktuel Traumatol* 13:34–41
32. Weber BG, Cech O (1973) Schenkelhals-pseudarthrose. In: Weber BG, Cech O (eds) *Pseudarthro sen: pathophysiology, biomechanics, therapy, results*. Verlag Hans Huber, Bern, pp 141–179
33. Catto M (1965) A histological study of avascular necrosis of the femoral head after transcervical fracture. *J Bone Joint Surg Br* 47-B:749–776
34. Raaymakers Ernst LFB, Marti Rene K (2008) Nonunion of the femoral neck: possibilities and limitations of the various treatment modalities. *Indian J Orthop* 42:13–21
35. Kirby H (2002) Femoral neck non-union: osteotomy or arthroplasty. *Tech Orthop* 17(4):434–442